



3D Printing Assisted Upper Thoracic Vertebra (T1-6) Fractures Instrumentation Üç Boyutlu Yazıcı Destekli Üst Torakal Kırıkların (T1-6) Enstrumantasyonu

¹Ceren Kizmazoglu, ¹Rifat Saygin Altinag, ¹Fazli Oguzhan Durak, ¹Ege Coskun,
²Resit Bugra Husemoglu, ³Ismail Kaya, ³Hasan Emre Aydin, ⁴Turan Kandemir,
¹Orhan Kalemci

¹Dokuz Eylul University School of Medicine, Department of Neurosurgery, Izmir, Turkey

²Dokuz Eylul University Health Science Institute, Department of Biomechanics, Izmir, Turkey

³Kutahya Health Science University, Department of Neurosurgery, Kutahya, Turkey

⁴Yunus Emre State Hospital Department of Neurosurgery, Eskisehir, Turkey

Abstract: Three dimensional (3D) printed models specific to the patients, decrease peroperative complications by providing preoperative surgical planning and application opportunities to the surgeon. The aim of this study is to determine the clinical results of preoperative surgical planning and application on 3D printed models, in patients with upper thoracic vertebral fracture treated via pedicle screw and posterior spinal fusion. 6 patients in total with upper thoracal fracture from our clinics were included to this study. 3D printer with custom design printing capability and lamellar printing technology was used for the production of 3D models. Preoperative surgical planning and application were performed on the models. The mean age of the patients was 47.16±13.40 (25-64). 4 (66.7%) of 6 patients were males and 2 (33.3%) were females. All presented after a history of trauma. The mean operation duration was 253.33±74.47 minutes (170-360). The mean duration of hospitalization was 13.83±9.06 days. Spinal instrumentation with the assistance from preoperative 3D models is an effective and reliable treatment for upper thoracic vertebral fractures. Use of the 3D models increases the ability of preoperative simulation in favor of the surgeon. This technique decreases the risk of screw malposition and shortens the operative duration thus enhances intraoperative reliability. **Keywords:** Surgical planning, Pilot hole, 3D printer, Upper thoracic fracture

Kizmazoglu C, Altinag R.S, Durak F.O, Coskun E, Husemoglu R.B, Kaya I, Aydin H.E, Kalemci O, 2019. 3D Printing Assisted Upper Thoracic Vertebral (T1-6) Fractures Instrumentation, *Journal of Medical Innovation and Technology*

Özet: Hastaya özgü 3B modeller, cerraha preoperatif olarak cerrahi planlama ve uygulama imkanı sunarak peroperatif komplikasyonları azaltmaktadır. Bu çalışmanın amacı, Üst torakal pedikül vidası tekniği kullanılarak posterior spinal füzyon yapılacak olan hastaların 3B yazıcı ile oluşturulan preoperatif modelleri üzerinde cerrahi planlama ve uygulamasının klinik sonuçlara etkisini araştırmaktır. Kliniklerimize atlantoaksiyel dislokasyon nedeniyle başvuran 6 hasta bu çalışmaya alınmıştır. Üç boyutlu baskı materyalinin üretimi için özel tasarımı katmanlı üretim teknolojisi olan üç boyutlu yazıcı kullanıldı. Preoperatif modeller üzerinde cerrahi planlama yapıldı ve uygulandı. Hastaların yaş ortalaması 47.16±13.40 (25-64) yaş idi. 6 hastanın 4'ü erkek(%66.7), 2'si kadındı (%33.3). Bu hastaların hepsi travma nedeniyle kliniğimize başvurdu. Hastaların operasyon süresi ortalama 253.33±74.47 dk (170-360). Hastaların ortalama yatış süresi 13.83±9.06 gündü. Preoperatif üç boyutlu modellemenin yardımı ile yapılan spinal enstrumantasyon, üst torakal kırık tedavisinde etkili bir yöntemdir. Bu modellerin kullanımı, ameliyat öncesi simülasyon yapma becerisini artırarak cerrahlara avantajlar sunar. 3B'lu modelleme tekniği ameliyat sırasında, vida malpozisyonu azaltır, ameliyat süresini kısaltarak intraoperatif güvenliği artırır.

Anahtar Kelimeler: Cerrahi planlama; Kılavuz delik; Üç boyutlu yazıcı, Üst torakal kırık

Kizmazoglu C, Altinag R.S, Durak F.O, Coşkun E, Husemoglu R.B, Kaya I, Aydın H.E, Kalemci O, 2019 Üç Boyutlu Yazıcı Destekli Üst Torakal Kırıkların (T1-6) Enstrumantasyonu, *Medikal İnovasyon ve Teknoloji Dergisi*

ORCID ID of the authors: C K 0000-0001-6146-0842, R.S.A 0000-0003-3355-0554, F.O.D 0000-0002-4741-1742, E.C 0000-0002-5582-9786, R.B.H 0000-0003-1979-160X, I.K 0000-0002-5117-8066, H E A 0000-0002-8932-1542, O K 0000-0002-8607-6860

Yazışma Adresi / Correspondence Address

Ceren KIZMAZOĞLU

mail: ceren.kizmazoglu@gmail.com

1. Introduction

Upper thoracic vertebral injuries mostly result of bending and axial stress with dislocation or rotational forces. These injuries are mostly seen in motorcyclists frequently at T4-T6 levels (1,2).

Spinal cord injury is common in patients with upper thoracic vertebral fractures given that spinal canal diameter is smaller at relevant segments. Complete paraplegia incidence is almost 80%. The advantages of surgical stabilization are correction of sagittal and coronal balance in kyphotic fractures and neurological decompression. Additionally, fixation and fusion prevent hyperkyphosis. Anatomical studies support that thoracic pedicle screw placement is more difficult at upper segments than lower due to narrower diameter of the pedicles (3).

3D printed models have been used at medical and surgical fields such as cranial structure, maxillofacial trauma, tissue engineering, vascular patches, thoracic deformities and complex spine surgery (4-6).

3D printer is a high-tech device that transforms a 3D model designed on computer to a physical object. Nowadays 3D technology has been used at preoperative evaluation of the patients anatomy, development of prosthesis and medical devices. 3D printers aid surgical success rates by enabling preoperative simulation of surgical approaches. 3D modelling is appears to be superior to 3D conventional neuroimaging. Similarly, the surgeons understanding the pathology by seeing and touching is better than only seeing it (4-7).

3D printed models specific to the patients, decrease peroperative complications by providing preoperative surgical planning and application opportunities to the surgeon. The aim of this study is to determine the clinical results of preoperative surgical planning and application on 3D printed models, in patients with upper thoracic vertebral fracture treated via pedicle screw and posterior spinal fusion.

2. Material and Methods

6 patients in total with upper thoracic fracture from two different clinics between 2017-2019 were included to this study.

Preparation and Printing of 3D Models

There are different steps in production of the 3D models. The data from thoracic computed tomography (CT) images are visualized in two dimensions. After processing according to several algorithms 3D visualization of the anatomy is achieved (8). In this study following steps were included: Obtaining the image for 3D printing, retouch after image processing and 3D model printing.

Obtaining the Image

In 3D model production, the quality of the printed object heavily depends on the quality of the data. The preoperative images were acquired by CT with 1 millimeter-thick slices. The data was recorded as DICOM (Digital Imaging and Communications in Medicine) format.

3D Model Processing

DICOM images from CT data were gone through segmentation process one by one by 3D Slicer. Afterwards surface texture improvements of the models were done. The retouched image was prepared and saved as STL (Surface Tesselation Language) format for 3D model printing.

The STL file was created via an open-source software Meshmixer Software (Autodesk, San Rafael, USA) using CAD drawing data. Therefore G-codes of models obtained. G-code data was transferred to the 3D printer and progressed to the printing process with thermoplastic material (filament). Polylactic acid (PLA) filaments, which is a thermoplastic material, was used during the printing of the models. 3D printer with custom design printing capability and lamellar printing technology (Fused Deposition Modelling) was used for the production of 3D models (Figure 1-3).

Statistical Analysis

Statistical Package for Social Sciences version 22.0 (SPSS, Chicago, IL, USA) was used for statistical analysis. The obtained data was used and the median and standard deviation values were calculated.

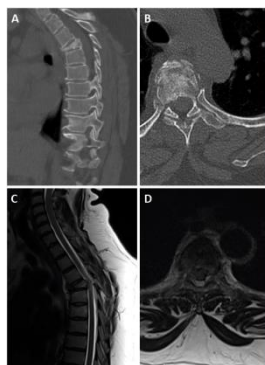


Figure 1.

T5 burst fracture, preoperative sagittal and axial computed tomography (A,B) and T2-weighted sagittal and axial MRI (C,D)




Figure 2.

DICOM images and preparation for printing as STL format by 3D Slicer and Meshmixer softwares respectively (A,B), Preoperative pilot hole preparation on 3D-printed model and pedicle screw application (C,D)

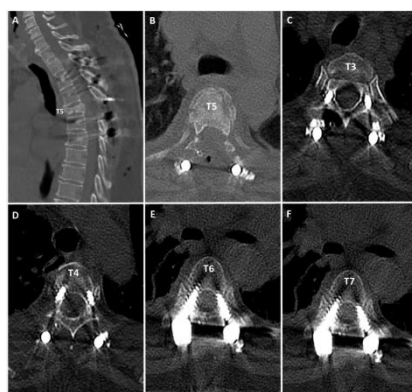

Figure 3.

Postoperative images of the patient undergone upper thoracic fusion (A-F)

3. Results

The mean age of the patients was 47.16 ± 13.40 (25-64). 4 (66.7%) of 6 patients were males and 2 (33.3%) were females. All presented after a history of trauma. Dural injury secondary to the trauma was present in 2 (33.3%) patients. These injuries were sutured via 5/0 polyglactin and fibrin glue was applied afterwards. Preoperative

and postoperative Frankel scores of the patients were shown on Table 1. One patient died on postoperative 27th day. The mean operation duration was 253.33 ± 74.47 minutes (170-360). The mean duration of hospitalization was 13.83 ± 9.06 days.

Table 1.

Summary of patients' age, sex, mechanism of injury, level of spinal injury, preoperative Frankel score, associated injuries, operation performed, postoperative Frankel scores and duration of hospitalization

Case	Age	Sex	Injury Mechanism	Level of spine Injured	Pre-op Frankel Scores	Associated Injuries	Operation	Post-op Frankel Scores	In- patient Stay (days)
1	55	F	Fall	T5	E	None	T3-4-6-7 PSE, T5 total laminectomy	E	4
2	41	M	Vehicular accident	T6	C	None	T4-5-6-7 PSE	C	16
3	25	M	Vehicular accident	T6	A	None	T4-5-7-8 PSE, T6 total laminectomy	A	9
4	46	M	Motorcycle accident	T6	E	Maxillofacial fracture	T4-5-7-8 PSE, T6 total laminectomy	E	12
5	52	F	Fall	T5	C	Rib fracture, Hemothorx	T3-4-6-7 PSE, T5 total laminectomy	C	21
6	64	M	Motorcycle accident	T6	A	Femur fracture	T4-5-7-8 PSE, T6 total laminectomy	A	27

4. Discussion

Posterior fusion has become one of the fundamental techniques for thoracic instability as further development of spinal surgery technology took place. With the aid of 3D printing technology the anatomy of planned surgery can be evaluated by the surgeon preoperatively.

Posterior approach is frequently used for upper thoracic fractures. Pedicles of upper thoracic vertebrae are thinner and positioned at differing angles for each vertebra (9). Vaccaro et al studied thoracic vertebrae on 17 human cadavers. Determined mean T4 pedicle diameter as 4.5 millimeters (mm) (10). In our study this measurement was 4.1 mm. The smaller diameter of thoracic vertebra pedicles causes difficulties in thoracic pedicle screw placement and increases risk of complications. Therefore, preoperative 3D modelling was suggested and pedicle cortical bone fracture rate was 12.5% (6/48). No revisions were needed. In our preoperative 3D models, pedicles and 3 mm-wide screw trajectories were marked with Meshmixer program. So the screw trajectories and angles were determined and studied preoperatively.

503 cadavers were studied in another study by Yu et al. Thoracic vertebra pedicle diameter was determined to be thicker in old, tall and overweight males (11). Vaccaro et al determined that 37 of 90 thoracic pedicle screws were malpositioned. 21 of them positioned medially heading towards spinal canal and 16 of them positioned laterally (12). Esophageal and aortic injuries are higher at upper thoracic screw

placement than other sites. Given that trajectories were determined preoperatively in our study, there were no esophageal or aortic injury.

A surgeon perceives the 3D structure evaluating the preoperative images. This perception differs from a surgeon to another. With 3D printing technology, a 3D-printed solid model consolidates the perceived 3D structure and increases preoperative orientation and concentration. The surgeon can determine screw dimensions preoperatively according to this solid model and prevent complications. Sterilization and use at operative field of the solid model enhances the success rate of optimising the pedicle screw trajectory. These models may improve the learning curve of young neurosurgeons. Better results with lesser number of attended surgeries might be possible. The operation duration therefore the duration of anesthesia, preoperative blood loss and the risk of infection can be decreased with the use of models.

Our study shows that fixation and fusion with the aid of preoperative 3D modelling is an effective treatment for upper thoracic vertebral injuries. Use of the 3D models increases the ability of preoperative simulation in favor of the surgeon. Preoperative screw malposition and duration of the operation are decrease with 3D modelling technique. Possibility of cheap and individualized modelling will increase the use of 3D modelling not only in neurosurgery practice but also in other fields in the future.

REFERENCES

1. Quinlan JF, Harty JA, O'Byrne JM. The need for multidisciplinary management of patients with upper thoracic spine fractures caused by high-velocity impact: a review of 32 surgically stabilised cases. *J Orthop Surg (Hong Kong)*. 2005;13(1):34-9.
2. Anthes TB, Muangman N, Bulger E, Stern EJ. Upper thoracic spine fracture dislocation in a motorcyclist. *Curr Probl Diagn Radiol*. 2012;41(4):128-9.
3. Payer M. Unstable upper and middle thoracic fractures. Preliminary experience with a posterior transpedicular correction-fixation technique. *J Clin Neurosci*. 2005;12(5):529-33.
4. Vakharia VN, Vakharia NN, Hill CS. Review of 3-Dimensional Printing on Cranial Neurosurgery Simulation Training. *World Neurosurg*. 2016;88:188-98.
5. Ploch CC, Mansi C, Jayamohan J, Kuhl E. Using 3D Printing to Create Personalized Brain Models for Neurosurgical Training and Preoperative Planning. *World Neurosurg*. 2016;90:668-74.
6. Xu W, Zhang X, Ke T, Cai H, Gao X. 3D printing-assisted preoperative plan of pedicle screw placement for middle-upper thoracic trauma: a cohort study. *BMC Musculoskelet Disord*. 2017;18(1):348.
7. Lador R, Regev G, Salame K, Khashan M, Lidar Z. Use of 3-Dimensional Printing Technology in Complex Spine Surgeries. *World Neurosurg*. 2019 Sep 11. pii: S1878-8750(19)32431-3. doi: 10.1016/j.wneu.2019.09.002. [Epub ahead of print]
8. Chen D, Chen CH, Tang L, Wang K, Li YZ, Phan K, Wu AM. Three-dimensional reconstructions in spine and screw trajectory simulation on 3D digital images: a step by step approach by using Mimics software. *J Spine Surg*. 2017;3(4):650-656.
9. Payer M. Unstable upper and middle thoracic fractures. Preliminary experience with a posterior transpedicular correction-fixation technique. *Clin Neurosci*. 2005;12:529-33.
10. Vaccaro AR, Rizzolo SJ, Allardice TJ, Ramsey M, Salvo J, Balderston RA. Placement of pediclescrews in the thoracic spine. Part I: Morphometric analysis of the thoracic vertebrae. *J Bone Joint Surg Am*. 1995;77(8):1193-9.
11. Yu CC, Bajwa NS, Toy JO, Ahn UM, Ahn NU. Pedicle morphometry of upper thoracic vertebrae: an anatomic study of 503 cadaveric specimens. *Spine*. 2005;39(20):1201-9.
12. Vaccaro A, Rizzolo SJ, Balderston RA, Allardice TJ, Garfin SR, Dolinskas C, An HS. Placement of pedicle screws in the thoracic spine. Part II: an anatomical and radiographic assessment. *J Bone Joint Surg Am*. 1995;77(8):1200-6.